

# Prostaglandin-Associated Periorbitopathy Syndrome in Glaucoma

---

## The Compendium

2<sup>nd</sup> Edition, March 2025

THIS DOCUMENT IS INTENDED FOR HEALTHCARE PROFESSIONALS ONLY

Developed with support from:



This compendium was developed in collaboration with leading experts in glaucoma.  
We would like to extend special thanks to:

- Prof. Tin Aung
- Dr Seng Kheong Fang
- Prof. Christopher Leung
- Dr Dexter Leung
- Prof. Catherine Liu
- Assoc. Prof. Manchima Makornwattana
- Prof. Ki Ho Park
- Prof. Lopilly Park
- Dr Rei Sakata
- Prof. Makoto Aihara  
*(1<sup>st</sup> Edition, December 2022)*
- Prof. Tina Wong  
*(1<sup>st</sup> Edition, December 2022)*

All patient images were granted permission for use and informed consent was obtained from patients. All information and images included in the compendium were provided, reviewed and validated by:

- Prof. Makoto Aihara
- Assoc. Prof. Weerawat Kiddee
- Dr Chien-Chia Su

# Table of Contents

---

<b>Executive Summary</b>	<b>1–6</b>
<b>Comprehensive Overview of PAPS</b>	<b>7–19</b>
Introduction	7
Etymology	8
Clinical Signs and Symptoms	8–9
Clinical Staging	10–11
Pathophysiology	11–12
Risk Factors	13
Epidemiology	14
Impact of PAPS on Patients	15–16
Prevention and Management of PAPS	16–19
<b>Summary</b>	<b>20</b>
<b>References</b>	<b>21–23</b>

# Executive Summary

## Introduction

Glaucoma is the leading cause of irreversible blindness worldwide.<sup>1, 2</sup> As a result of a globally aging population, the proportion of individuals affected by glaucoma is increasing over time; this is predicted to disproportionately affect the Asian and African populations, due to the large population sizes and increasing life expectancy in these regions.<sup>2</sup> As such, it is important to consider ways of optimising management strategies for glaucoma to reduce both the disease and treatment burden on patients.

The goal of glaucoma management is to maintain a patient's quality of vision and quality of life.<sup>3</sup> This is generally achieved through the control of intraocular pressure (IOP). IOP-lowering medications are commonly used in the treatment of glaucoma as they are effective in stabilising vision for most patients, have a generally acceptable therapeutic index and are widely available.<sup>3</sup> In particular, topical prostaglandin analogues (PGAs; also known as prostanoid prostaglandin F [FP] receptor agonists) are popular first-line agents for the treatment of glaucoma due to their potent IOP-lowering efficacy, few systemic side-effects and once-daily regimens, which can help promote patient adherence.<sup>4</sup> However, their use has been reported to induce periocular changes and the development of local periorbital side-effects, with the incidence and time to development of these changes varying with the type of PGA used and underlying patient risk factors.<sup>4</sup> These periocular changes and periorbital symptoms related to topical PGA use are collectively described as prostaglandin-associated periorbitopathy syndrome (PAPS).<sup>5-7</sup>

## Objectives

The objective of this compendium is to:

- Provide a comprehensive overview of the current knowledge of PAPS
- Describe the impact of PAPS on patients
- Highlight key areas of uncertainty in the field (such as the clinical staging of PAPS)
- Delineate potential prevention and management strategies

This document additionally aims to raise awareness of PAPS in the Asia-Pacific (APAC) region, with the hope of catalysing further scientific and medical collaboration in the pursuit of strategies to manage or mitigate PAPS during the treatment of glaucoma.

## Clinical Signs and Symptoms

Although more studies are required to define the signs and symptoms of PAPS, a range of clinical and cosmetic changes are currently included under the umbrella term "PAPS".

Commonly reported signs and symptoms include:<sup>4, 7-13</sup>

- Hyperpigmentation of the periorbital skin
- Eyelash trichomegaly and hypertrichosis
- Deepening of upper eyelid sulcus (DUES)
- Flattening of the lower eyelid bags
- Upper eyelid ptosis
- Mild enophthalmos
- Orbital fat atrophy
- Tight orbit syndrome (TOS)
- Inferior scleral show
- Involution of dermatochalasis

## Clinical Staging

Two notable methods of grading PAPS are outlined by Rabinowitz et al. (2015) and Tanito et al. (2021) (**Table 1**).<sup>14, 15</sup> Of the two systems, glaucoma specialists have noted the relevance of the Shimane University PAP (SU-PAP) grading system by Tanito et al. (2021) for patients in the APAC region.<sup>16, 17</sup> However, each approach has its own unique limitations. In addition, the reliance on subjective measurements for certain signs of PAPS, the uncertainty that surrounds the breadth of changes that might constitute PAPS and the subtlety of some of these signs, confound attempts to establish a reliable and comprehensive grading system that could garner broad consensus amongst ophthalmologists.

**Table 1.** Existing PAPS grading systems

Rabinowitz <i>et al.</i> (2015) <sup>14</sup>	
Grade	Description
1	Relative fat atrophy with grade 1 superior sulcus deformity (SSD) (i.e., no SSD)
2	Fat atrophy with grade 2 SSD (early SSD – skin of the superior sulcus is involuted but remains at the superior orbital rim)
3	Relative fat atrophy with grade 3 SSD (severely sunken SSD – sulcus rests posterior to the orbital rim in the sagittal plane)
Strengths	
<ul style="list-style-type: none"> <li>• May be useful for the quantification of PAPS in clinical trials</li> </ul>	
Limitations	
<ul style="list-style-type: none"> <li>• May be considered too complex for use in real-world situations<sup>15</sup></li> <li>• Does not account for difficulty in performing IOP measurements<sup>15</sup></li> </ul>	
SU-PAP, Tanito <i>et al.</i> (2021) <sup>a,15</sup>	
Grade	Description
0	No PAPS (no cosmetic change by macroscopic or slit-lamp observation)
1	Superficial cosmetic PAPS (cosmetic changes including eyelid pigmentation and/or eyelash growth)
2	Deep cosmetic PAPS (cosmetic changes with at least one sign of PAPS including DUES, blepharochalasis involution, periorbital fat loss or enophthalmos)
3	Tonometric PAPS (difficulty performing Goldmann applanation tonometry [GAT] and/or reduced reliability of GAT-measured IOP due to PAPS-related DUES, hardening of eyelids, ptosis or enophthalmos)
Strengths	
<ul style="list-style-type: none"> <li>• Simpler than Rabinowitz <i>et al.</i> (2015)</li> <li>• Unites cosmetic and tonometric aspects of PAPS</li> <li>• May correlate with differences observed in the frequency and severity of PAPS by topical PGA use</li> <li>• May facilitate clinician grading of PAPS in the presence of complications</li> <li>• May be more relevant for patients in the APAC region<sup>3, 16, 17</sup></li> </ul>	
Limitations	
<ul style="list-style-type: none"> <li>• Does not consider the subjectivity of PAPS, whereby a given symptom, or set of symptoms, could be considered a cosmetic improvement by some patients</li> <li>• It may therefore be more practical to view cosmetic aspects of PAPS and tonometric assessments separately</li> </ul>	

<sup>a</sup>Tanito *et al.* (2021) use the term “PAP” rather than PAPS.<sup>15</sup>

Abbreviations: APAC: Asia-Pacific; DUES: deepening of upper eyelid sulcus; GAT: Goldmann applanation tonometry; IOP: intraocular pressure; PAP: prostaglandin-associated periorbitopathy; PAPS: prostaglandin-associated periorbitopathy syndrome; PGA: prostaglandin analogue; SSD: superior sulcus deformity; SU-PAP: Shimane University PAP.

**The Asia-Pacific Glaucoma Society (APGS) recommends considering the use of the SU-PAP grading system as a practical guideline for assessing the severity of PAPS in clinical practice.<sup>18</sup>**

There is also currently no consensus on how best to measure the impact of PAPS on patients. Certain symptoms of PAPS (e.g., eyelash trichomegaly and hypertrichosis) may be perceived as either a positive or negative cosmetic change by patients, depending on the symptom, its severity and the patient's cosmetic preference.<sup>7</sup> Consequently, a tool for recording the patient-reported impact of PAPS would need to capture both the change observed, and how the symptom is subjectively classified by the patient as either a cosmetic improvement or an adverse event.

**In conjunction with a clinical grading system, a patient-reported tool may encourage self-evaluation of PAPS symptoms, and facilitate a more comprehensive and personalised clinical management of PAPS.<sup>17</sup>**

Consequently, there remains an unmet need for a comprehensive and robust clinical grading system, which either incorporates, or is affiliated with, a tool that captures the subjective impact of PAPS on the patient. Such a grading system could ensure that PAPS is identified early and managed appropriately, which may facilitate further research, thereby raising awareness amongst ophthalmologists and patients.

## Risk Factors and Epidemiology

Several potential risk factors for PAPS have been identified, though further research is required to further elucidate and establish causal relationships.<sup>15, 19-24</sup>

The perceived epidemiology of PAPS may consequently be influenced by a complex interplay of risk factors at the geographic, population and individual patient levels.

These risk factors can be grouped into three main categories:

### 1. The use of PGAs known to cause PAPS

- Bimatoprost (BIM) and travoprost (TRAV) have been identified as stronger risk factors for DUES and other PAPS symptoms, compared with latanoprost (LAT) and tafluprost (TAF) which also demonstrate PAPS symptoms, albeit at a lower reported incidence.<sup>7, 15, 21-25</sup> Consequently, clinicians that use BIM or TRAV to lower IOP may observe a higher incidence of PAPS among their patients.
- However, the relationship between duration of topical PGA administration and PAPS remains unclear. Although larger studies have found no significant association between PAPS and duration

of PGA use, some smaller studies have cited manifestation of specific clinical signs of PAPS (e.g., DUES) at 3–6 months of PGA use.<sup>8, 23, 24, 26, 27</sup>

### 2. Patient-specific risk factors

- Older age (in particular, >60 years) is significantly associated with PAPS.<sup>8, 15, 23</sup> As such, countries with a greater proportion of older individuals may have a higher prevalence of PAPS.
- Patients with improper eyedrop instillation technique may be at a greater risk of developing localised side-effects (and consequently PAPS), if excess fluid is not properly removed from contact with surrounding skin and hair.<sup>19, 20</sup> In particular, patients with comorbidities that affect mobility (e.g., arthritis) may be at risk of poor eyedrop instillation technique.<sup>19</sup>
- Populations in the APAC region may be more susceptible to PAPS compared with patients in other parts of the world. For example, periorbital hyperpigmentation is common amongst people of South Asian (e.g., Indian) ethnicity, with ophthalmologists noting a higher number of melanocytes in the periocular area.<sup>26, 28</sup> This is thought to predispose Indian patients to more severe periocular hyperpigmentation from PGA use.<sup>28</sup> In addition, East Asian patients may be more sensitive to DUES due to a lack of superior sulcus depression; therefore, cosmetic changes to this ocular region may be more pronounced.<sup>8</sup> Furthermore, given periorbital fat atrophy induced by PGA use can contribute towards developing TOS,<sup>10</sup> some populations in the APAC region with less periorbital fat at baseline may be more susceptible to TOS, relative to those with more periorbital fat at baseline.

### 3. The degree to which clinicians, patients and friends or family are likely to notice and report cosmetic changes

- Detection of PAPS can be dependent on the awareness of patients, friends and family of the link between PGAs and periorbital cosmetic changes. Furthermore, clinicians may not necessarily detect changes associated with PAPS, as these changes are often subtle.<sup>21, 29</sup>
- Specific demographic groups, such as younger or more image-conscious individuals, may be more sensitive to cosmetic changes of PAPS.<sup>30, 31</sup> Patients administering unilateral therapy may also be more likely to identify and report cosmetic changes due to facial asymmetry.<sup>32</sup>
- Overall, there is a lack of epidemiological data on

PAPS and observed differences between ethnicities and populations are mainly anecdotal, based on clinician observations and experience. Further research is required to substantiate these hypotheses and preliminary findings.

## Impact of PAPS on Patients

### Cosmetic Changes

For many patients with glaucoma, the cosmetic changes associated with PAPS are considered undesirable.

Patients who require unilateral therapy for glaucoma may be particularly unwilling to tolerate the potential facial asymmetry that could result from topical PGA use.<sup>26, 32</sup> Therefore, there is an unmet need for effective IOP-lowering medications that can be used unilaterally, without inducing facial asymmetry.

Younger patients, who are active in their professional lives, especially those who require face-to-face interaction in their jobs, may also be more image-conscious and may therefore be less likely to use or adhere to PGAs.<sup>30</sup>

### Difficulty Measuring IOP

Clinicians have previously noted the negative impacts that certain PAPS signs, such as ptosis, DUES and tight upper eyelid tissue, have on obtaining reliable IOP measurements using GAT. In particular, it is difficult to lift a tight lid without applying pressure on the globe in the presence of DUES and no pre-septal fat, which would invalidate the GAT measurement.<sup>15, 33</sup> Furthermore, literature suggests that PAPS symptoms may also lead to TOS, which has been linked to overestimated IOP measurements.<sup>10</sup>

#### **Prolonged use of PGAs is significantly associated with developing TOS.<sup>10</sup>**

- In one study, patients with TOS had more advanced disease, were treated more aggressively, and for longer than patients without TOS.<sup>10</sup>
- Despite maximum medical therapy and surgical intervention, TOS is also associated with poor IOP control and consequently, progressive and rapid visual field loss.<sup>33</sup>
- Furthermore, tight eyelids in TOS can make it difficult to perform GAT,<sup>33</sup> which complicates the detection and subsequent management of IOP in patients with TOS.

TOS was first linked to topical PGA use in 2014 during a case-control study,<sup>10</sup> and has since been characterised as a symptom of PAPS.<sup>34</sup> However,

TOS may be more adequately characterised as a sequela of PAPS, arising from PAPS-associated orbital fat atrophy.

### Surgical Complications

Performing surgery in patients with PAPS presents unique challenges, including difficulties in the placement of the eyelid speculum due to enophthalmos and tight eyelids.<sup>15</sup> Surgical outcomes can vary depending on the pre-operative PGA used; a review of medical records has suggested a high risk of recurrent IOP elevation up to 2 years post-trabeculectomy in patients who used BIM before surgery compared with LAT, TAF and TRAV. The incidence of DUES associated with different PGAs was postulated to be a factor, with PGA-induced eyelid hardening also hypothesised to contribute to poor prognosis.<sup>35</sup> Given that the severity of PAPS can also affect surgical outcomes, and that PAPS is preventable, physicians may consider switching or stopping causative medications to avoid progression to severe PAPS.<sup>36</sup>

## Prevention and Management of PAPS

### Step 1: First consultation – patient education on PAPS

**The APGS recommends considering PAPS when initiating glaucoma treatment for naïve patients.<sup>18</sup> Treatments that do not increase risk for PAPS may be suitable for the following patient profiles:<sup>37</sup>**

- Patients who are concerned about cosmetic appearance
- Existing patients using PGA who have experienced ocular side-effects

Firstly, all patients (including those who are treatment-naïve), may benefit from advice on proper eyedrop instillation technique (e.g., washing the face and eyelids with water after using PGAs and rinsing the periocular area following administration).<sup>20, 38</sup> Clinicians could consider providing educational materials on PAPS to raise awareness among patients and manage treatment expectations, thereby potentially avoiding PAPS-related non-adherence to PGAs. This may include an introduction to PAPS and its risk factors, as well as re-assurance on how PAPS is managed.

Clinicians should also be attentive towards patients who may have PAPS concerns (e.g., patients with unilateral glaucoma, office-working/customer-facing, have an active social lifestyle, or have naturally tight

orbits etc), and patients who are at high risk of developing PAPS (e.g., patients with existing PAPS, or TOS).<sup>4, 10, 39, 40</sup>

## Step 2: Active PAPS monitoring and assessment of patient concerns

Secondly, patients should be proactively monitored throughout treatment to provide opportunity to raise concerns, especially among patients in the PAPS-concern or PAPS-high risk groups.

**Patient groups that clinicians may wish to be especially attentive towards include:<sup>4, 10, 39, 40</sup>**

- **PAPS-concern group (patients with unilateral glaucoma, office-working/customer-facing, have an active social lifestyle, or have naturally tight orbits)**
- **PAPS high-risk group (patients with existing PAPS, or TOS)**

If a patient presents with PAPS, the SU-PAP system can be used to assess PAPS severity and guide subsequent action. In cases of no or mild PAPS (SU-PAP Grades 0–1), clinicians should proactively check for PAPS concerns and address them. If no concerns are raised, a ‘watch-and-wait’ approach may be appropriate.<sup>16</sup> In contrast, for patients who present with moderate/severe PAPS (SU-PAP Grades 2–3), swift and aggressive management may be required.<sup>16</sup> Alternative medications (different class, corticosteroids, or frequent lubrication) should be considered as appropriate.<sup>3, 41</sup>

## Step 3: PGA cessation and switch to alternative management

Thirdly, PGA cessation and subsequent switching to alternative anti-glaucoma agents may be required for patients with mild PAPS who become intolerant of PAPS, and for patients with moderate to severe PAPS who require swift and aggressive management.<sup>16</sup>

**Some ophthalmologists have suggested that compiling baseline patient photos may be helpful for detecting and monitoring the development of PAPS.<sup>17</sup>**

### PGA cessation

Many of the cosmetic and clinical changes associated with topical PGA use are reversible through discontinuation of the causative therapy. A partial or complete reversal has been reported as early as 4–6 weeks after discontinuation.<sup>4</sup> However, prolonged use

of PGAs can lead to development of deep cosmetic PAPS or tonometric PAPS.<sup>10</sup> Severe PAPS may be irreversible,<sup>4, 42</sup> which can have a direct, negative impact on long-term glaucoma management.<sup>4, 5, 10, 33, 35, 41–43</sup>

When managing PAPS for existing patients on PGAs, the APGS recommends considering PGA cessation as PAPS is usually reversible on discontinuation of PGAs.<sup>18</sup>

**Though the exact degree of reversibility has not been formally investigated, the reversibility of PAPS may be influenced by the specific PGA used and individual patient characteristics.<sup>16</sup>**

Following PGA cessation, the subsequent steps for managing PAPS and glaucoma concurrently should be individualised to the patient’s treatment plan and goals. Factors to consider include target IOP, risk of disease progression and patient preference.<sup>3</sup>

### Switching treatment

- **In case PGA cessation is not suitable, switching to another PGA** associated with a lower likelihood of PAPS (e.g., LAT or TAF) could be considered, particularly where a positive response in IOP is observed upon treatment switch.<sup>13, 15, 21–24</sup> The APGS recommends switching to a PGA associated with a lower likelihood of PAPS.<sup>18</sup> For example, LAT and TAF can be effective in reducing DUES.<sup>13, 21, 43</sup>
- **Switching to another class of anti-glaucoma medication** that is similarly effective at lowering IOP may also be a viable option. For example, a unilateral trial of an  $\alpha$ -agonist (e.g., brimonidine) or  $\beta$ -blocker (e.g., timolol) could be considered.<sup>3</sup>
  - Use of more than one alternative agent could be considered in patients with PAPS if each agent has demonstrated efficacy but is insufficient in achieving target IOP as monotherapy.<sup>3</sup>

Of note, prostanoid prostaglandin E2 receptor agonists (EP2 agonists) do not have a prostaglandin chemical structure but induce similar IOP-lowering effects to PGAs.<sup>4, 30, 44</sup> However, they do not result in FP receptor-associated hypertrichosis and periorbital fat atrophy.<sup>4, 30</sup> In addition, studies have reported improvements in PAPS upon switching from PGAs to EP2 agonists.<sup>45</sup> EP2 agonists could therefore be considered as an alternative to PGAs when aiming to avoid PAPS, and be

used as first-line drugs in terms of IOP lowering efficacy and tolerability.<sup>4, 30, 46</sup>

- Switching treatment to an alternative that does not cause PAPS can also positively contribute towards an improvement in patients' perception of PAPS symptoms, which has been linked to an increase in treatment satisfaction.<sup>47</sup>
- **Laser treatment**, such as selective laser trabeculoplasty, is relatively effective, non-invasive and can help to circumvent issues related to medical non-adherence.<sup>3</sup> Where indicated, laser treatment may be a viable alternative to manage IOP in patients with glaucoma who develop PAPS when treated with PGAs.
- **Surgery** for glaucoma can also be effective in lowering IOP where topical medications and/or laser treatment have failed or are deemed unlikely to provide satisfactory IOP control.<sup>3</sup> Patients receiving PGAs, who fail on or are contraindicated to alternative medications and/or laser treatment, could consider surgical intervention to manage their glaucoma without causing PAPS. Notably, allowing time between PGA cessation and surgery may improve surgical outcomes, as reversal of some of the physical changes associated with PAPS may lessen surgical complications.<sup>35</sup>

## Conclusions

Although the primary goal in the management of glaucoma is to preserve visual function and quality of life, it is important to also consider the potential impact of PAPS when making treatment choices to achieve IOP control. Due to the undesirable clinical and cosmetic consequences of PAPS, this group of side-effects can have an adverse physical and psychological impact on patients receiving treatment for glaucoma using PGAs. Several approaches to the clinical staging of PAPS have been proposed,<sup>14, 15</sup> with the SU-PAP grading system specifically recommended by APGS as a practical guideline for assessing the severity of PAPS,<sup>18</sup> and is also recognised by glaucoma specialists to be relevant in the APAC region.<sup>16, 17</sup>

A range of potential management strategies currently exist, including the cessation of the causative treatment and switching to alternative therapies as recommended by the AGPS.<sup>18</sup> However, there is still a paucity of evidence to inform the prioritisation of therapeutic interventions. Further formal integration of these strategies into future glaucoma guidelines could standardise a PAPS-inclusive treatment pathway across the APAC region, aiding ophthalmologists in managing PAPS during glaucoma treatment.

# Comprehensive Overview of PAPS

## Introduction

Glaucoma is the leading cause of irreversible blindness worldwide.<sup>1, 2</sup> Of all forms of glaucoma, primary open angle glaucoma (POAG) is the most common, accounting for ~70% of glaucoma cases worldwide.<sup>48, 49</sup> Some other forms of glaucoma have been observed more commonly in specific ethnic populations of the Asia-Pacific (APAC) region. For example, a higher prevalence of primary angle closure glaucoma (PACG) has been reported among Asian patients compared with those of European, African, or Hispanic ancestry in a systematic review and meta-analysis.<sup>2</sup> A separate study among patients of Japanese descent also observed that the proportion of patients with normal-tension glaucoma was four-fold higher than that of patients with high-tension glaucoma.<sup>50</sup>

As a result of a rapidly aging global population, the proportion of individuals affected by blindness due to glaucoma is increasing.<sup>1</sup> Further increases in the number of people with glaucoma worldwide over the next two decades are anticipated to have a disproportionate effect in Asia and Africa due to the large population sizes and increasing life expectancy in these regions.<sup>2</sup> As such, it is important to consider ways of optimising management strategies for glaucoma to reduce both disease and treatment burden on patients.

The goal of glaucoma management is to maintain a patient's quality of vision and quality of life.<sup>3</sup> This is generally achieved through the control of intraocular pressure (IOP). For primary glaucoma, this can be achieved through the cessation of drugs that may elevate IOP (e.g., steroids) and employing IOP-lowering drugs, laser treatment or surgery; whereas for secondary glaucoma, the underlying pathology contributing to raised IOP should be addressed.<sup>3</sup> IOP-lowering medications are commonly used in the treatment of glaucoma as they are effective for most patients, have a generally acceptable therapeutic index and are widely available.<sup>3</sup> These can be divided by drug class and further classified by mechanism of action (**Table 2**).<sup>3</sup>

Notably, topical prostaglandin analogues (PGAs; also known as prostanoid prostaglandin F [FP] receptor agonists) are popular first-line agents for the treatment of glaucoma due to their potent IOP-lowering efficacy, few systemic side-effects and once-daily regimens, which can help to promote patient adherence.<sup>4</sup> However, their use has been reported to induce progressive periocular changes and the development of local periorbital side-effects. These symptoms are collectively described as prostaglandin-associated periorbitopathy syndrome (PAPS).<sup>4</sup>

**Table 2.** Commonly used glaucoma treatment options

Mechanism of Action	Drug Class (Therapeutic Effect)
Increase in aqueous outflow	PGAs; also known as prostanoid FP receptor agonists ( <i>increase in uveoscleral outflow</i> ) <sup>30</sup>
	α-Agonists ( <i>increase in uveoscleral outflow</i> )
	Cholinergics ( <i>increase in trabecular outflow</i> )
	Rho-kinase inhibitors ( <i>increase in trabecular outflow</i> )
Decrease in aqueous inflow	Prostanoid EP2 receptor agonists ( <i>increase both in trabecular and uveoscleral outflow</i> ) <sup>30</sup>
	α-Agonists
	β-Blockers
	Carbonic anhydrase inhibitors

Adapted from: Asia Pacific Glaucoma Guidelines, 4<sup>th</sup> Edition (2024).<sup>3</sup>

Abbreviations: EP2: prostaglandin E2; FP: prostaglandin F; PGA: prostaglandin analogue.

## Etymology

The first mention of periocular changes and periorbital symptoms related to topical PGA use occurred in case reports published in 2004 and 2008.<sup>5-7</sup> In a study by Peplinski and Albani Smith (2004), alteration of the eyelid appearance with deepening of the upper eyelid sulcus (DUES) was observed in three patients treated with unilateral bimatoprost (BIM).<sup>5</sup> Filippopoulos *et al.* (2008) observed periorbital fat atrophy, DUES, relative enophthalmos, lower eyelid fullness and involution of dermatochalasis in five non-consecutive patients treated unilaterally for glaucoma with BIM 0.03%.<sup>6</sup> However, terms such as "deep superior sulcus syndrome" and DUES did not necessarily encompass the full range of symptoms that were being linked with topical PGA treatment.<sup>7</sup>

In 2011 the term "Prostaglandin-Associated Periorbitopathy" (PAP) was coined by Dr Stanley Berke and Dr Louis Pasquale.<sup>7, 11</sup> "PAP" comprises eight clinical findings in patients treated with PGAs:<sup>7</sup>

1. Upper eyelid ptosis
2. DUES
3. Involution of dermatochalasis
4. Periorbital fat atrophy
5. Mild enophthalmos
6. Inferior scleral show
7. Increased prominence of eyelid vessels
8. Tight eyelids

In addition to these clinical findings, topical PGAs were also associated with cosmetic changes, such as lengthening and darkening of the eyelashes, hyperpigmentation of the periorbital skin and changes in the colour of the iris.<sup>7</sup> Sarnoff and Gotkin (2015) highlighted that such cosmetic changes could be perceived as an improvement in the overall appearance of the periorbital area by certain patients. In addition, they suggested that involution of dermatochalasis, DUES, periorbital fat atrophy and tightening of the eyelid skin can simulate a blepharoplasty in some individuals.<sup>7</sup> Consequently, the term "Prostaglandin-Associated Periorbital Syndrome" was proposed, whereby the inclusion of "syndrome" was intended to more accurately refer to these changes as a group of side-effects associated with topical PGA use, rather than as a disease.<sup>7</sup>

In this compendium, PAPS refers to the constellation of clinical and cosmetic signs and symptoms that have been linked to topical PGA use.

## Clinical Sign and Symptoms

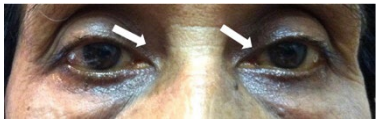


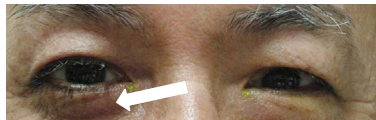




A range of clinical and cosmetic changes are included under the umbrella term "PAPS".<sup>4</sup> Commonly reported signs and symptoms are outlined in **Table 3**. Of note, individual signs and symptoms of PAPS are not mutually exclusive and often occur simultaneously.<sup>4, 6, 7, 9, 26</sup> A singular event in isolation (e.g., eyelash lengthening) may not necessarily be considered PAPS, but instead a side-effect of PGA use.

**Although signs and symptoms of PAPS often occur simultaneously in patients, ophthalmologists in APAC note that certain signs or symptoms of PAPS may develop sequentially.<sup>16</sup>**

In Kim *et al.* (2020), patients with a history of childhood glaucoma treated with unilateral PGAs for at least 12 months exhibited eyelash trichomegaly and hypertrichosis (n=22, 76%), high upper eyelid crease (n=20, 69%), upper eyelid ptosis (n=14, 52%) and superior sulcus hollowing (n=15, 52%) in their PGA-treated eyes. Overall, 20–30% of patients were observed to have moderate eyelash and/or eyelid changes.<sup>9</sup> These periocular changes and periorbital symptoms were therefore similar to commonly reported signs and symptoms of PAPS among the broader adult population (**Table 3**).

There is currently neither a definitive nor exhaustive list of PAPS signs and symptoms, due to a paucity in data as well as the wide variability and subtlety of these signs. As such, there may be other side-effects that have not yet been definitively associated with PGA use. For example, a case report published in 2016 observed clicking eyelids in a patient using BIM, alongside other more common symptoms of PAPS (e.g., eyelash hypertrichosis, tight eyelids, DUES), suggesting that clicking eyelids may be a new audible sign/symptom associated with PAPS. However, this has not previously been reported in the literature.<sup>51</sup> Whilst a core set of signs and symptoms of PAPS has now been identified across the literature, such case reports suggest that there is a need to further define the signs and symptoms of PAPS, alongside their frequency of occurrence.

**Table 3.** Commonly reported PAPS signs and symptoms

Ranking <sup>38</sup>	PAPS Signs and Symptoms	Patient Images After PGA Treatment <sup>38</sup>
1	Hyperpigmentation of the periorbital skin <sup>4, 8, 9</sup>	 <p>Image courtesy of Dr Weerawat Kiddee.</p>
2	Eyelash trichomegaly and hypertrichosis <sup>4, 9</sup>	 <p>Image courtesy of Dr Chien-Chia Su.</p>
3	Deepening of the upper eyelid sulcus <sup>4, 8, 9</sup>	 <p>Image courtesy of Prof. Makoto Aihara.</p>
4	Flattening of the lower eyelid bags <sup>4</sup>	 <p>Image courtesy of Prof. Makoto Aihara.</p>
5	Upper eyelid ptosis <sup>4, 9</sup>	 <p>Image courtesy of Dr Chien-Chia Su.</p>
6	Mild enophthalmos <sup>4, 8, 9</sup>	 <p>Image courtesy of Dr Chien-Chia Su.</p>
7	Orbital fat atrophy <sup>4, 8</sup>	 <p>Image courtesy of Dr Weerawat Kiddee.</p>
8	Tight orbit syndrome <sup>a, 4, 10</sup>	 <p>Image courtesy of Prof. Makoto Aihara.</p>
9	Inferior scleral show <sup>4</sup>	<i>No image available</i>
10	Involution of dermatochalasis <sup>4, 9</sup>	<i>No image available</i>

<sup>a</sup>Tight orbit syndrome may be more appropriately characterised as a sequela of PAPS, rather than a symptom.  
Abbreviations: PAPS: prostaglandin-associated periorbitopathy syndrome; PGA: prostaglandin analogue.

## Clinical Staging

Several methods of grading PAPS have been proposed in the literature, notably by Rabinowitz et al. (2015) and Tanito et al. (2021) (**Table 4**).<sup>14, 15</sup> In brief, Rabinowitz et al. (2015) stratified treated eyelids and adnexa into three categories.<sup>14</sup> Tanito et al. (2021) subsequently proposed the Shimane University PAP (SU-PAP) grading system, classifying PAPS into four grades, based on appearance and difficulty in performing Goldmann applanation tonometer (GAT) readings.<sup>15</sup>

**Table 4.** Existing PAPS grading systems

Rabinowitz et al. (2015) <sup>14</sup>	
Grade	Description
1	Relative fat atrophy with grade 1 superior sulcus deformity (SSD) (i.e., no SSD)
2	Fat atrophy with grade 2 SSD (early SSD – skin of the superior sulcus is involuted but remains at the superior orbital rim)
3	Relative fat atrophy with grade 3 SSD (severely sunken SSD – sulcus rests posterior to the orbital rim in the sagittal plane)
SU-PAP, Tanito et al. (2021) <sup>a,15</sup>	
Grade	Description
0	No PAPS (no cosmetic change by macroscopic or slit-lamp observation)
1	Superficial cosmetic PAPS (cosmetic changes including eyelid pigmentation and/or eyelash growth)
2	Deep cosmetic PAPS (cosmetic changes with at least one sign of PAPS including DUES, blepharochalasis involution, periorbital fat loss or enophthalmos)
3	Tonometric PAPS (difficulty performing Goldmann applanation tonometry [GAT] and/or reduced reliability of GAT-measured IOP due to PAPS-related DUES, hardening of eyelids, ptosis or enophthalmos)

<sup>a</sup>Tanito et al. (2021) use the term “PAP” rather than PAPS.<sup>15</sup>

Abbreviations: DUES: deepening of upper eyelid sulcus; GAT: Goldmann applanation tonometry; IOP: intraocular pressure; PAP: prostaglandin-associated periorbitopathy; PAPS: prostaglandin-associated periorbitopathy syndrome; SSD: superior sulcus deformity; SU-PAP: Shimane University PAP.

Though Rabinowitz et al. (2015) has been noted as a useful grading system for the quantification of PAPS in clinical trials, ophthalmologists may consider the grading approach to be too complex to use in real-world situations.<sup>15</sup> Furthermore, this approach does not incorporate the tonometric implications of PAPS (i.e., difficulty in performing IOP measurements) as part of the grading system.<sup>14, 15</sup>

In contrast, SU-PAP is a simpler grading system, which unites cosmetic and tonometric aspects of PAPS and appears to correlate with differences observed in the frequency and severity of PAPS by topical PGA used.<sup>15</sup> Of the two systems, glaucoma specialists have noted the relevance of the Shimane University PAP (SU-PAP) grading system by Tanito et al. (2021) for patients in the APAC region.<sup>16, 17</sup> However, while unifying cosmetic and tonometric aspects of PAPS enhances the comprehensiveness of the SU-PAP system, ophthalmologists may consider it to be more practical to measure these implications of PAPS separately, with the option of then being able to combine both assessments for a unified score.

**The Asia-Pacific Glaucoma Society (APGS) recommends considering the use of the SU-PAP grading system as a practical guideline for assessing the severity of PAPS in clinical practice.<sup>18</sup>**

Furthermore, neither clinical staging method considers the subjectivity of the impact of PAPS on the patient. This is important, as certain symptoms of PAPS may be perceived as either a positive or negative cosmetic change by patients, depending on the symptom, its severity and the patient’s cosmetic preference.<sup>7, 14, 15</sup> Consequently, a tool for recording patient-reported impacts of PAPS would need to capture both the change observed and how the symptom is subjectively classified by the patient, as either a cosmetic improvement or an adverse event.<sup>7</sup>

**In conjunction with a clinical grading system, a patient-reported tool may encourage self-evaluation of PAPS symptoms, and facilitate a more comprehensive and personalised clinical management of PAPS.<sup>17</sup>**

Given the limitations of current approaches suggested by Rabinowitz et al. (2015) and Tanito et al. (2021), there remains an unmet need for a comprehensive and robust grading system for PAPS. While there are clear challenges to the creation of a comprehensive grading system for PAPS, its development could support the early identification and appropriate management of

PAPS. Additional assessments proposed for grading PAPS (e.g., exophthalmometry, lid laxity, differences between tonometry results, baseline measurements, and external ocular photographs) may complement these approaches and help drive a more systematic grading of PAPS.<sup>17</sup> These in turn may facilitate further research into PAPS, thereby raising awareness of PAPS amongst ophthalmologists and patients. As such, clinical staging of PAPS represents a priority area for further research.

## Pathophysiology

Since the identification of PAPS, several studies have investigated the possible mechanisms that might generate the different signs and symptoms observed. Evidence suggests that the mechanisms by which PGAs cause PAPS are multi-factorial, with different molecular pathways postulated to be associated with different symptoms.<sup>7</sup>

PGAs are synthetically derived prostaglandin  $F_{2\alpha}$  ( $PGF_{2\alpha}$ ) analogues.<sup>7</sup> Long-term treatment with  $PGF_{2\alpha}$ -derivatives in pre-clinical models demonstrates a long-lasting reduction in IOP, which persists following treatment cessation. This long-term effect is likely due to the expansion of the intermuscular spaces in the ciliary body through extracellular matrix (ECM) remodelling.<sup>52, 53</sup> PGAs lower IOP through agonistic binding to the prostanoid FP receptor, which is present in the tissues of the uveoscleral outflow pathway (iris, ciliary body and sclera). Binding of PGAs to the FP receptor in uveoscleral tissue upregulates the expression of matrix metalloproteinases (MMPs), which degrade the ECM of the ciliary body, creating intermuscular spaces through which aqueous humour can leave the eye, thereby lowering IOP.<sup>30, 54, 55</sup>

However, the effect of PGAs on MMPs and tissue inhibitors of metalloproteinases (TIMP) is postulated to be tissue-specific, with decreased expression of certain MMPs identified in collagen. Pre-clinical models suggest that decreased expression of certain MMPs in collagen correlates with increased periorbitopathy.<sup>4, 56</sup> In addition, PGA-induced ECM remodelling may result in dysregulation of the ECM scaffold, which may have implications for ptosis and other eyelid malpositions.<sup>56</sup> While PGA-mediated upregulation of MMPs in uveoscleral tissue generates therapeutic IOP reductions, ECM remodelling may therefore also play a role in PAPS.

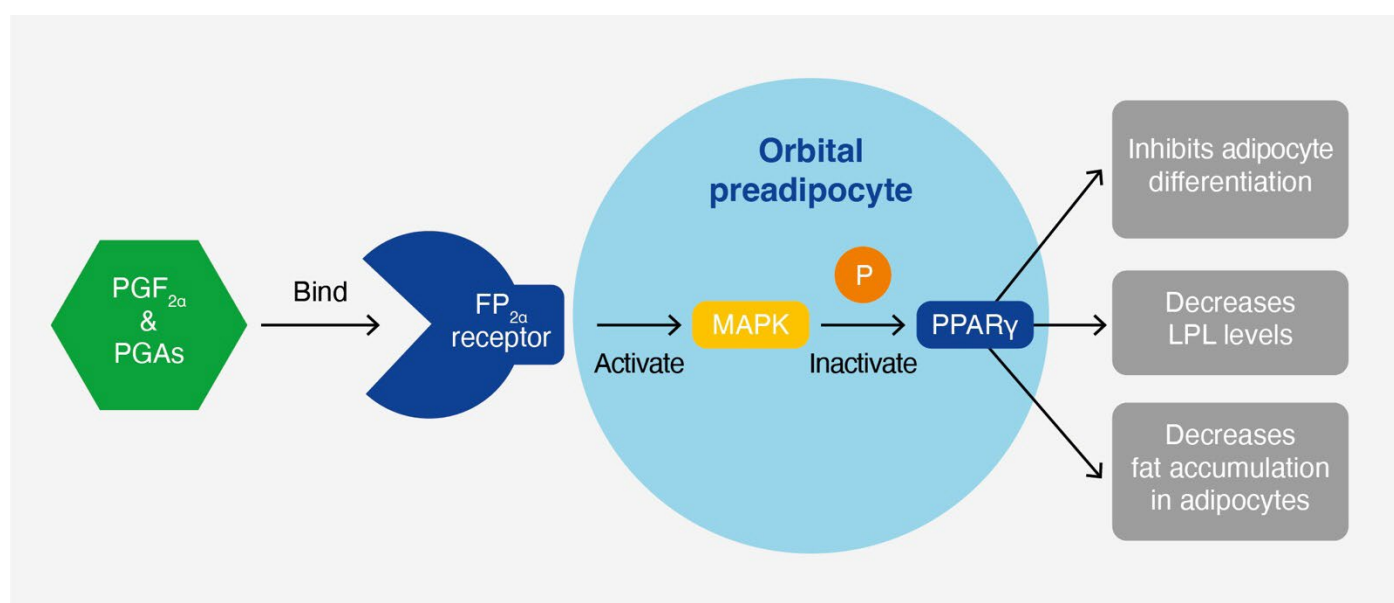
In addition, PGAs bind to the FP receptor on orbital pre-adipocytes.<sup>7, 57</sup> This binding activates mitogen-activated protein kinase (MAPK), resulting in phosphorylation and inactivation of peroxisome proliferator-activated receptor gamma (PPAR $\gamma$ ) (**Figure 1**). Inhibition of PPAR $\gamma$  prevents adipocyte differentiation, decreases lipoprotein lipase (LPL) levels (a marker for adipocyte differentiation) and decreases fat accumulation within adipocytes.<sup>4, 57-60</sup> PGA-induced suppression of other adipogenic transcription factors, such as CCAAT/enhancer binding protein  $\alpha$  and  $\beta$  has also been observed in murine cells.<sup>61</sup> These mechanisms have been postulated to lead to the reduced orbital fat observed in DUES,<sup>29, 61</sup> and may contribute to other symptoms of PAPS

related to orbital fat atrophy, such as involution of dermatochalasis.<sup>7</sup>

The degree of adipogenesis inhibition has been found to vary by the specific PGA used. An *in vitro* study found that BIM acid suppressed adipogenesis, even at a low concentration (1nM), while low concentrations of latanoprost (LAT) acid did not.<sup>29</sup>

Exposure to PGAs, even for a short duration, can promote increased length and thickness of eyelashes. This is due to PGAs acting as a stimulus for the initiation of the anagen phase of the hair growth cycle by binding to the prostaglandin receptors on eyelashes and ancillary hair follicles around the eyelids. In addition, topical PGA use is thought to produce additional lash rows by increasing the proportion of

hairs in the anagen phase versus telogen phase, converting vellus hairs (soft, short, unmedullated and unpigmented) to terminal hairs (coarse, longer, medullated and pigmented) in the canthal areas and increasing growth and pigmentation of ancillary hairs around the eyelids.<sup>4, 62, 63</sup> In addition, *in vitro* studies have suggested that FP-agonists affect melanogenesis and melanocyte proliferation.<sup>15, 64, 65</sup> Iris hyperpigmentation, where brown pigment near the pupil spreads concentrically towards the periphery, has been postulated to occur due to upregulation of tyrosinase gene transcription.<sup>7, 66</sup> However, the mechanisms by which topical PGAs might induce prostaglandin-associated periocular skin or iris pigmentation have not been fully explored.



**Figure 1.** Mechanism of action and impact of PGAs on orbital pre-adipocytes

Source: Adapted from Sakata et al. (2021).<sup>4</sup>

Abbreviations: FP2α: prostaglandin F2α; LPL: lipoprotein lipase; MAPK: mitogen-activated protein kinase; P: phosphorylation; PGA: prostaglandin analogue; PGF2α: prostaglandin F2α; PPARγ: peroxisome proliferator-activated receptor gamma.

## Risk Factors

Potential risk factors for PAPS are outlined in **Table 5**. Variability in the prevalence of PAPS and the time taken to develop PAPS has been observed with treatment using different PGAs, as well as between individuals. Overall, more data and research will be required to elucidate and establish risk factors for PAPS.

**Table 5.** Risk factors for PAPS

Risk Factor	Description
Type of PGA	<ul style="list-style-type: none"> <li>BIM and TRAV have been consistently identified as strong inducers of DUES and other PAPS symptoms, whereby 40.0–93.3% of patients receiving BIM and 24.0–70.0% of patients receiving TRAV may experience PAPS.<sup>15, 21-24</sup></li> <li>On the other hand, studies found that LAT and TAF were weaker inducers of PAPS, whereby 6.0–41.4% of patients receiving LAT and 9.0–18.0% receiving TAF may experience PAPS.<sup>13, 15, 21-24</sup></li> <li>These findings are concordant with Taketani <i>et al.</i> (2014), who reported that BIM acid suppressed adipogenesis in vitro at much lower concentrations than LAT.<sup>29</sup></li> </ul>
Duration of PGA use	<ul style="list-style-type: none"> <li>The relationship between duration of topical PGA use and PAPS is unclear.</li> <li>Although it may be a reasonable assumption to expect duration of PGA use to be an independent risk factor for DUES and other PAPS symptoms, current evidence is inconclusive. While larger studies have not found a consistent, significant association between PAPS and duration, some smaller studies have cited manifestation of specific clinical signs of PAPS (e.g., DUES) at 3–6 months of PGA use.<sup>8, 23, 24, 26, 27</sup> Further research into this association is required.</li> </ul>
Age	<ul style="list-style-type: none"> <li>Older age (in particular, &gt;60 years) was found to be significantly associated with PAPS.<sup>8, 15, 23</sup></li> <li>As DUES following PGA administration has been attributed to orbital fat atrophy, use of PGAs, particularly BIM, may aggravate pre-existing age-associated orbital fat atrophy.<sup>8</sup></li> </ul>
Improper eyedrop instillation technique	<ul style="list-style-type: none"> <li>Improper eyedrop instillation technique of PGAs may contribute to localised side-effects if excess fluid is not properly removed from contact with surrounding skin and hair.<sup>20, 21</sup> In particular, patients with comorbidities that affect mobility (e.g., arthritis) may be at risk of poor eyedrop instillation technique.<sup>20</sup></li> </ul> <div> <p><b>Patients are advised to carefully clean any excess eyedrops from the periorbital area; practical recommendations may include washing off excess medication, cleaning with a wet wipe, or using a tissue to gently absorb spilled eyedrops.<sup>20</sup> Notably, wiping spilled eyedrops with a tissue may spread medication to the lower eyelid and exacerbate certain side-effects of PGAs, which may potentially contribute towards PAPS.<sup>16, 20</sup></b></p> <p><b>In addition, some ophthalmologists have anecdotally suggested that older patients often administer PGAs before bed in the supine position, which could increase their risk of PAPS (e.g., patients may fall asleep without washing off excess medication).<sup>16</sup></b></p> </div>

Abbreviations: BIM: bimatoprost; DUES: deepening of the upper eyelid sulcus; LAT: latanoprost; PAPS: prostaglandin-associated periorbitopathy syndrome; PGA: prostaglandin analogue; TAF: tafluprost; TRAV: travoprost.

## Epidemiology

As PAPS is a clinical consequence of treatment with topical PGAs, the epidemiology of PAPS is likely to be influenced by three main factors.

### 1. The use of PGAs known to cause PAPS

Some studies have observed a stronger association between BIM or travoprost (TRAV) and developing PAPS symptoms (DUES in particular), compared with other PGAs (e.g., LAT). Countries, institutions, or clinicians that favour BIM or TRAV to lower IOP in their patients may therefore observe a higher incidence of PAPS (DUES in particular).<sup>21, 22, 24</sup>

### 2. Patient-specific risk factors

Patients with certain comorbidities affecting mobility, such as arthritis, could experience difficulty in instilling eyedrops accurately. This group of patients may therefore be at a higher risk of developing localised side-effects (and consequently, PAPS) if excess fluid is not properly removed from contact with surrounding skin and hair.<sup>19, 20</sup>

More broadly, populations in the APAC region may be more susceptible to PAPS compared with patients in other parts of the world. Periorbital hyperpigmentation is common amongst people of South Asian (Indian) ethnicity, with ophthalmologists noting a higher number of melanocytes in the periocular area of Indian patients.<sup>26, 28</sup> This is thought to predispose Indian patients to more severe periocular hyperpigmentation from PGA use.<sup>28</sup> East Asian patients, however, may be more sensitive to DUES due to a lack of superior sulcus depression, and so cosmetic changes to this ocular region may be more pronounced.<sup>8</sup> Furthermore, given periorbital fat atrophy induced by PGA use can contribute towards developing TOS,<sup>10</sup> some populations in the APAC region with less periorbital fat at baseline may be more susceptible to TOS, relative to those with more periorbital fat at baseline.

### 3. The degree to which clinicians, patients and friends or family are likely to notice and report cosmetic changes

Changes associated with PAPS are not always easily identifiable; detection of PAPS can be dependent on the awareness of patients, friends and family of the link between PGAs and periorbital cosmetic changes.<sup>21, 29</sup>

Certain populations may be more sensitised to cosmetic changes. For example, younger or image-conscious individuals may be more likely to report cosmetic changes caused by PGAs.<sup>30</sup> Cosmetic changes could also be more apparent to patients who administer PGAs unilaterally, due to resulting facial asymmetry.<sup>32</sup> An overall societal shift towards higher

image consciousness may also contribute towards increased detection of PAPS.<sup>31</sup>

**Anecdotes suggest that older populations may be more indifferent to cosmetic changes and may confound symptoms of PAPS with the natural signs of aging. Furthermore, some patients may hesitate to highlight symptoms of PAPS to their clinician, due to the superiority of IOP reduction and their perceived risk-to-benefit ratio of using PGAs.<sup>16</sup> Consequently, although social awareness and the predisposition of people to notice and report periocular changes do not affect the underlying pathophysiology, these social factors may attenuate or amplify the detection of PAPS in certain populations.**

**The variety of cosmetic changes associated with PAPS, particularly in the early stages, may confound a clinician's ability to make a differential diagnosis due to the similarity of PAPS signs to other periorbital conditions (e.g., allergic conjunctivitis). Geographical variations in the sensitisation of clinicians to PAPS may therefore additionally affect the degree to which PAPS is detected and reported.<sup>16</sup>**

Overall, there is a lack of epidemiological data on PAPS and observed differences between ethnicities and populations are mainly anecdotal, based on clinician observations and experience. Further research is required to substantiate these hypotheses and preliminary findings.

## Impact of PAPS on Patients

### Cosmetic changes

For many PGA-users, the cosmetic changes associated with PAPS are considered undesirable. In particular, patients who require unilateral PGA therapy may be unwilling to tolerate the potential facial asymmetry that could result from topical PGA use (**Figure 2**).<sup>26, 32</sup> Therefore, there is an unmet need for effective IOP-lowering medications that can be used unilaterally, without inducing facial asymmetry.

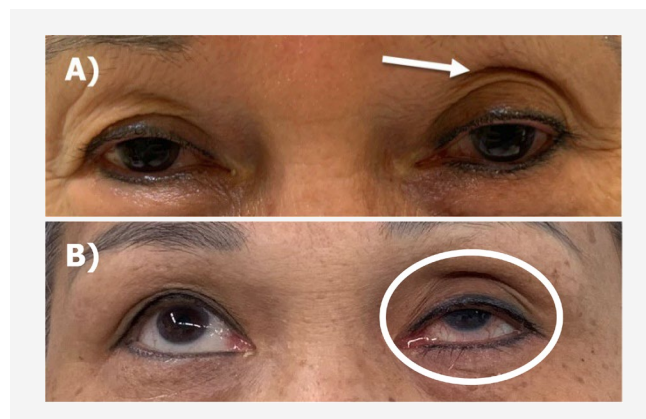Groups of patients who are less likely to consider cosmetic side-effects, such as skin hyperpigmentation or facial asymmetry, to be desirable include younger patients or individuals who are active in their professional lives (especially those who require face-to-face interaction in their jobs), and those who are generally more image-conscious.<sup>30</sup> These "unacceptable" cosmetic side-effects may potentially lead to poorer adherence to PGAs compared with other anti-glaucoma agents.

**Female patients are often more sensitive to cosmetic changes; however, certain cosmetic changes associated with PAPS (e.g., eyelash trichomegaly) may be viewed particularly adversely by male patients.<sup>16</sup>**

**As young people may already have deep-set eyes, prescribing these patients PGAs may lead to a "sunken" appearance with severely deep-set eyes which, along with darkening of the periorbital skin,<sup>67</sup> are among the most cosmetically unacceptable symptoms for patients.<sup>16</sup>**

It is important to note that PAPS exhibits some degree of reversibility upon PGA cessation. In earlier cases of PAPS observed in patients treated with unilateral BIM, symptoms were observed to partially reverse upon discontinuation of treatment.

However, despite the general negative perceptions of cosmetic changes associated with PAPS, some PAPS-associated cosmetic changes could be considered cosmetically desirable by specific individuals. For example, a specific preparation of BIM was approved by the Food and Drug Administration of the United States for eyelash enhancement (Latisse® [topical BIM solution, 0.03%; Allergan, Inc., Irvine, CA]).<sup>7</sup>



**Figure 2.** Photographs of facial asymmetry associated with PAPS

Source: Images courtesy of Dr Chien-Chia Su.

### Difficulty measuring IOP

Clinicians have previously noted the negative impacts that certain PAPS signs, such as ptosis, DUES and tight upper eyelid tissue, have on obtaining reliable IOP measurements using GAT. In particular, it is difficult to lift a tight lid without applying pressure on the globe in the presence of DUES and no pre-septal fat, which would invalidate the measurement.<sup>15, 33</sup> These patients have been described as "GAT challenges".<sup>11</sup>

Some of these physiological changes can lead to tight orbit syndrome (TOS).<sup>15</sup> TOS is a condition characterised by eyelids that press firmly against the globe, limiting globe exposure during tonometry, gonioscopy and surgery, combined with a high-pressure glaucoma that is extremely difficult to manage.<sup>33</sup>

### **Prolonged use of PGAs is significantly associated with developing TOS.<sup>10</sup>**

- **In one study, patients with TOS had more advanced disease, were treated more aggressively, and for longer than patients without TOS.<sup>10</sup>**
- **Despite maximum medical therapy and surgical intervention, TOS is also associated with poor IOP control and consequently, progressive and rapid visual field loss.<sup>33</sup>**
- **Furthermore, tight eyelids in TOS can make it difficult to perform GAT,<sup>33</sup> which complicates the detection and subsequent management of IOP in patients with TOS.**

TOS was first linked to topical PGA use in 2014 during a case-control study,<sup>10</sup> following which TOS has been characterised as a symptom of PAPS.<sup>34</sup> However, TOS may be more adequately characterised as a

sequela of PAPS, arising from the PAPS-associated orbital fat atrophy. TOS is therefore a serious clinical challenge.<sup>33</sup> Further research is required to better characterise TOS, its association with PAPS and its clinical impact on treatment.

## Surgical complications

Performing surgery in patients with PAPS presents unique challenges, including difficulties in the placement of the lid speculum due to enophthalmos and tight eyelids.<sup>15</sup> Surgical outcomes may also vary depending on the pre-operative PGA used. A retrospective review of medical records of POAG patients who underwent primary trabeculectomy due to PGA failure suggested a high risk of recurrent IOP elevation up to 2 years post-trabeculectomy in patients who used BIM before surgery, compared with LAT, tafluprost (TAF) and TRAV. Specifically, the difference in incidence of DUES, depending on the PGA used, was postulated to be a factor, with PGA-induced eyelid hardening also hypothesised to contribute to poor post-surgical prognosis.<sup>35</sup>

The severity of PAPS can also affect surgical outcomes. Patients with POAG and more severe PAPS (e.g., SU-PAP Grades 2–3) pre-surgery had worse 1-year post-trabeculectomy success rates than patients with no PAPS (SU-PAP Grade 0) or mild PAPS (SU-PAP Grade 1).<sup>36</sup> Given PAPS is preventable, it may be reasonable for physicians to consider switching or stopping causative medications to avoid progression to severe PAPS.<sup>36</sup>

Further investigation into the consequences of pre-operative PAPS on surgical outcomes is required to quantify its effects and develop appropriate clinical management recommendations.

## Prevention and Management of PAPS

Use of topical anti-glaucoma medications can cause periorbital changes that may be overlooked by ophthalmologists, but have potential to reduce drug tolerability, quality of life, and drug adherence for the patient.<sup>41</sup> There are multiple strategies to prevent and/or manage PAPS; however, the approach taken should be individualised to the patient. PAPS can be avoided by using non-PGA alternatives; however, given the efficacy of PGAs, their safety and convenience (once-daily regimens), many clinicians opt for PGAs as the first-line medication despite the risk of PAPS.<sup>4, 18</sup> Nonetheless, it is important to proactively and regularly monitor whether there is onset of PAPS in patients using topical PGAs.<sup>18, 41</sup>

While in certain cases clinicians may wish to monitor mild PAPS (with patient consent), strategies for managing PAPS primarily entail PGA cessation and consideration of glaucoma agents, laser treatment or surgery.<sup>3</sup> Patient education on eyedrop instillation should also be considered where relevant to minimise the risk of improper instillation generating certain signs of PAPS (e.g., eyelid pigmentation).<sup>20, 38</sup>

### Step 1: First consultation – patient education on PAPS

**The APGS recommends considering PAPS when initiating glaucoma treatment for naïve patients.<sup>18</sup> Treatments that do not increase risk for PAPS may be suitable for the following patient profiles:<sup>37</sup>**

- Patients who are concerned about cosmetic appearance
- Existing patients using PGAs who have experienced ocular side-effects

Firstly, advising on the proper use of PGAs may be helpful for all patients (including those who are treatment-naïve), given that improper eyedrop instillation technique may contribute to local side-effects.<sup>19, 20, 38</sup> For example, it is advised to only instil one drop at a time – not several drops or a stream of drops – to avoid spillage of excess liquid.<sup>19</sup> Washing the face and eyelids too long after using PGAs (e.g., beyond 5 minutes) could result in excess medication being absorbed by the surrounding skin, resulting in hyperpigmentation.<sup>20</sup> Conversely, rinsing immediately after instilling eyedrops could risk the medication being rinsed away.<sup>19, 20, 38</sup>

In general, clinicians could consider providing educational materials on PAPS to raise awareness

among patients and manage treatment expectations, thereby potentially avoiding PAPS-related non-adherence to PGAs. This may include an introduction to PAPS and its risk factors to ensure that patients' expectations of treatment are managed.

Clinicians should also be attentive towards patients who may have PAPS concerns (e.g., patients with unilateral glaucoma, office-working/customer-facing, have an active social lifestyle, or have naturally tight orbits etc), and patients who are at high risk of developing PAPS (e.g., patients with existing PAPS, or TOS).<sup>4, 10, 39, 40</sup>

## Step 2: Active PAPS monitoring and assessment of patient concerns

Secondly, patients should be proactively monitored throughout treatment to provide opportunity to raise concerns, especially among patients in the PAPS-concern or PAPS-high risk groups.

**Patient groups that clinicians may wish to be especially attentive towards include:**<sup>4, 10, 39, 40</sup>

- **PAPS-concern group (patients with unilateral glaucoma, office-working/customer-facing, have an active social lifestyle, or have naturally tight orbits)**
- **PAPS high-risk group (patients with existing PAPS, or TOS)**

If a patient presents with PAPS, the SU-PAP system can be used to assess PAPS severity and guide subsequent action. In cases of no or mild PAPS (SU-PAP Grades 0–1), clinicians should proactively check for PAPS concerns and address them. If no concerns are raised, a 'watch-and-wait' approach may be appropriate.<sup>16</sup> In contrast, for patients who present with moderate/severe PAPS (SU-PAP Grades 2–3), swift and aggressive management may be required.<sup>16</sup> Alternative medications (different class, corticosteroids, or frequent lubrication) should be considered as appropriate.<sup>3, 41</sup>

## Step 3: PGA cessation and switch to alternative management

Thirdly, PGA cessation and subsequent switching to alternative anti-glaucoma agents may be required for patients with mild PAPS who become intolerant of PAPS, and for patients with moderate to severe PAPS who require swift and aggressive management.<sup>16</sup>

**Some ophthalmologists have suggested that compiling baseline patient photos may be helpful for detecting and monitoring the development of PAPS.**<sup>17</sup>

### PGA cessation

Certain cosmetic and clinical changes associated with topical PGA use are reversible through discontinuation of the causative therapy. A partial or complete reversal has been reported as early as 4–6 weeks after discontinuation.<sup>4</sup> However, prolonged use of PGAs can lead to development of deep cosmetic PAPS or tonometric PAPS.<sup>10</sup> Severe PAPS may be irreversible,<sup>4, 42</sup> which can have a direct, negative impact on long-term glaucoma management.<sup>4, 5, 10, 33, 35, 41–43</sup>

When managing PAPS for existing patients on PGAs, the APGS recommends considering PGA cessation as PAPS is usually reversible on discontinuation of PGAs.<sup>18</sup>

**Though the exact degree of reversibility has not been formally investigated, the reversibility of PAPS may be influenced by the specific PGA used and individual patient characteristics.**<sup>16</sup>

Following PGA cessation, the subsequent steps for managing PAPS and glaucoma concurrently should be individualised to the patient's treatment plan and goals.<sup>3</sup> Factors to consider when choosing the subsequent treatment would include target IOP, risk of disease progression and patient preference.<sup>3</sup>

It may additionally be helpful to consider contraindications to the use of PGAs at first discussion of pharmacological treatment. Contraindications include:<sup>3</sup>

- Cataract surgery complicated by posterior rupture and vitreous loss
- Herpes simplex keratitis (active or quiescent)
- Active inflammatory ocular conditions

- Cystoid macular oedema
- Known hypersensitivity to any component of the product
- Pregnancy

### Switching treatment

As some PGAs have been associated with a higher risk of PAPS than others, switching to an alternative, "lower-risk" PGA could be considered in case PGA cessation is not suitable, particularly where a positive response in IOP is observed upon switching treatment.<sup>3, 13, 15, 21-24</sup> In this situation, the APGS recommends switching to a PGA associated with a lower likelihood of PAPS.<sup>18</sup> For example, LAT and TAF can be effective in reducing DUES.<sup>13, 21, 43</sup>

**In clinical practice, patients are often switched from BIM to LAT to check if similar control of IOP can be achieved with the latter,<sup>16</sup> given that BIM is associated with a higher risk of certain signs of PAPS.<sup>15, 21-23</sup>**

Alternatively, switching to another class of anti-glaucoma drug that is similarly effective at lowering IOP may be a viable option. This could include anti-glaucoma agents from any of the common drug classes listed in **Table 2**. The choice of alternative medication should be made with consideration to its efficacy, safety profile, convenience, affordability, contraindications and likelihood of patient adherence.<sup>3</sup> The dosing frequency and reported IOP-lowering efficacy of commonly used anti-glaucoma agents are summarised in **Table 6**.

When switching to another class of anti-glaucoma drug in an attempt to manage PAPS, it is recommended to start "low and slow" (minimal concentration and frequency) and consider a unilateral trial of the agent where appropriate.<sup>3</sup>

**Table 6.** Dosing frequency and efficacy of various anti-glaucoma drug classes

Drug Class	Dosage	Efficacy (IOP Reduction)
PGAs (also known as prostanoid FP receptor agonists)	OD	25–35%
Prostanoid EP2 receptor agonists	OD	15–35%
β-Blockers	OD–BD	20–25%
α <sub>1</sub> -Blockers	BD	15–20%
α <sub>2</sub> -Agonists	BD–TDS	18–25%
α <sub>1</sub> β-Blockers	BD	20%
Topical carbonic anhydrase inhibitors	BD–TDS	20%
Systemic carbonic anhydrase inhibitors	BD–QDS	30–40%
Rho-kinase inhibitors	OD–BD	20–25%
Cholinergics	TDS–QDS	20–25%

Adapted from: Asia Pacific Glaucoma Guidelines, 4<sup>th</sup> Edition (2024).<sup>3</sup>  
 Abbreviations: BD: twice-daily; EP2: prostaglandin E2; FP: prostaglandin F; OD: once-daily; PGA: prostaglandin analogue; QDS: four times daily; TDS: three times daily.

### Prostanoid EP2 receptor agonists

In contrast with PGAs, which have high specificity for the prostanoid FP receptor, prostanoid EP2 receptor agonists (EP2 agonists) bind selectively to the prostanoid EP2 receptor. Given the pathophysiology of PAPS, EP2 agonists are therefore thought to have similar IOP-lowering properties to PGAs, but without resulting in FP receptor-associated changes.<sup>4, 30</sup> The Japanese Glaucoma Society also recommends that EP2 agonists could be used as first-line drugs in terms of IOP lowering efficacy and tolerability.<sup>46</sup> Furthermore, preliminary evidence suggests improvements in certain PAPS signs, particularly DUES, flattening of the lower eyelid bags and periorbital skin hyperpigmentation, one year after switching from a PGA to an EP2 agonist.<sup>45</sup> In a recent study, subjective questionnaires showed that DUES and eyelid skin pigmentation improved seven months after switching from a PGA to an EP2 agonist.<sup>47</sup>

Omidenepag isopropyl 0.002% (OMDI [EYBELIS®, Santen]), the only commercialised EP2 agonist to date, is a novel EP2 agonist that lowers IOP by facilitating uveoscleral and trabecular outflow.<sup>4, 30</sup> OMDI sustained effective IOP reduction for up to 12 months across patients with different glaucoma treatment regimens

(naïve monotherapy, switching therapy, concomitant therapy), with a persistence rate of up to 82.4% over 12 months.<sup>68</sup> It has demonstrated non-inferior efficacy to LAT with once-daily dosing and also resulted in a sustained reduction in IOP over 52 weeks in patients with open-angle glaucoma and ocular hypertension.<sup>69</sup> <sup>70</sup> In patients who were non-responsive to LAT and switched to OMDI, there was a clinically significant reduction in IOP from baseline.<sup>71</sup> In patients with normal-tension glaucoma and open angle glaucoma, OMDI use led to sustained IOP reduction for up to 3 years.<sup>72, 73</sup> Furthermore, unlike PGF2α analogues, OMDI does not appear to induce changes to the eyelashes or cause periorbital fat loss; recovery of DUES has also been observed after switching from PGAs to OMDI.<sup>4, 30</sup> In terms of safety, OMDI was found to have an acceptable safety and tolerability profile, with no serious treatment-related adverse events.<sup>25, 30</sup> <sup>70</sup> OMDI has been associated with conjunctival hyperaemia, increased central corneal thickness, ocular inflammation and macular oedema; it is also contraindicated in aphakic and pseudophakic eyes.<sup>25</sup> <sup>30</sup> Longer-term safety studies are required to establish the exact cause of the aforementioned adverse events and their time course during treatment.<sup>4, 30, 70</sup> Considering the efficacy and safety profile of OMDI, novel agents such as EP2 agonists broaden the treatment landscape for patients on medical treatment for glaucoma.<sup>37</sup>

**The APGS notes that OMDI is suitable for patients of any age from a wide range of patient profiles (who still have phakic eyes), including:<sup>37</sup>**

- Patients who are concerned about cosmetic appearance
- Treatment-naïve patients on monotherapy
- Existing patients using PGA who have experienced ocular side-effects

## Laser treatment and surgery

Laser treatment can be used in both POAG (argon or selective laser trabeculoplasty) and PACG (laser iridotomy). It is relatively effective, non-invasive and can help to circumvent issues related to medical non-adherence. Where indicated, laser treatment may potentially be an alternative to manage IOP in some patients with glaucoma.<sup>3</sup> Consequently, this may be helpful in achieving IOP control in patients who develop PAPS while receiving PGAs.

Surgery for glaucoma (e.g., minimally invasive glaucoma surgery [POAG], iridectomy [PACG] and trabeculectomy [POAG, PACG]) can also be effective in lowering IOP, particularly where topical medications and/or laser treatment have failed or are deemed unlikely to provide satisfactory IOP control.<sup>3</sup> Patients receiving PGAs who fail or have contraindications to alternative medications and/or laser treatment could consider surgical intervention to manage their glaucoma without causing PAPS. Allowing time between PGA cessation and surgery may improve surgical outcomes, as reversal of some of the physical changes associated with PAPS may lessen surgical complications.<sup>35</sup>

## Combination treatment

Use of more than one alternative agent in combination could be considered in patients with PAPS if each agent has demonstrated efficacy but remains insufficient to reach target IOP as a monotherapy. This consideration would also apply to the individual active ingredients in fixed combination preparations. Clinicians should not combine two drugs with the same mechanism of action, or use two fixed combinations containing active ingredients in overlapping categories.<sup>3</sup>

## Summary

Studies into the mechanisms by which PGAs cause PAPS suggest that the process is multifactorial, with PGF<sub>2α</sub>-induced fat atrophy and dysregulation of the hair growth cycle believed to cause a cluster of key signs and symptoms.<sup>7, 13</sup> There is currently neither a definitive nor exhaustive list of PAPS signs and symptoms, with new signs continuing to be reported in the academic literature. PAPS tends to have cosmetic effects through periorbital changes; however, these cosmetic changes can also have implications for clinical management, with certain symptoms, such as TOS, inhibiting attempts to obtain reliable IOP measurements using GAT and increasing the likelihood of trabeculectomy failure.<sup>10, 15, 26, 30, 32, 33, 35</sup> Therefore, measuring IOP in patients with TOS, and subsequently managing TOS, can be challenging. These patients are also often treated more aggressively, and for longer than patients without TOS.<sup>10</sup> Despite maximum medical therapy and surgical intervention, TOS is associated with poor IOP control and, consequently, progressive and rapid visual field loss.<sup>33</sup> Commonly reported signs and symptoms include hyperpigmentation of the periorbital skin, hypertrichosis, DUES, flattening of the lower eyelid bags and upper eyelid ptosis.<sup>4, 7-13</sup>

While mounting evidence suggests that BIM and TRAV are stronger inducers compared with LAT and TAF,<sup>13, 15, 21-24</sup> the relationship between duration of topical PGA use and PAPS remains unclear.<sup>8, 23, 24, 26, 27</sup> Some evidence also suggests that certain populations may be predisposed to develop PAPS (e.g., those aged >60 years).<sup>8, 15, 23</sup> However, the detection of PAPS may ultimately be dependent on the awareness of patients, friends and family of the link between PGAs and periorbital cosmetic changes, as changes associated with PAPS can often be subtle.<sup>21, 29</sup>

Several approaches to the clinical staging of PAPS have been proposed.<sup>14, 15</sup> The SU-PAP grading system has been suggested by the APGS as a practical guideline for assessing the severity of PAPS,<sup>18</sup> and is recognised by glaucoma specialists to be relevant in the APAC region.<sup>16, 17</sup> However, there is no consensus on how to measure the patient-reported impact of PAPS, as certain symptoms may be perceived as either a neutral, positive or negative cosmetic change, depending on the symptom, its severity and the patient's cosmetic preference. Further research is therefore required to develop both a PAPS grading system that is

comprehensive and captures the patient-reported impact of PAPS, taking into account the subjectivity in how changes may be perceived.<sup>7, 14, 15</sup>

A three-step approach can be used for the prevention and management of PAPS for a wide range of patient profiles, including patients concerned about cosmetic appearance, treatment-naïve patients on monotherapy, and existing patients using PGA who have experienced PAPS. The three-step approach begins with a first consultation to educate patients on PAPS. Clinicians should subsequently proactively check for signs of PAPS or if the patients have any concerns with at regular follow-up appointments. If concerns or signs of PAPS are noted, subsequent management should be tailored to the degree of PAPS severity. This may include PGA cessation, use of non-PGA alternatives (such as EP2 agonists), laser treatment or surgery if indicated.<sup>18, 30</sup>

Nevertheless, with the number of patients presenting to clinical services with glaucoma predicted to increase in Asia,<sup>2</sup> use of PGAs may rise to meet this demand. Therefore, the uncertainty that currently exists across multiple facets of PAPS necessitates action from the clinical community to generate evidence that can continue to help build consensus on defining, diagnosing, classifying and managing PAPS.

## References

1. Flaxman SR, Bourne RRA, Resnikoff S, et al. Global causes of blindness and distance vision impairment 1990–2020: a systematic review and meta-analysis. *Lancet Glob Health* 2017;5:e1221–34.
2. Tham YC, Li X, Wong TY, et al. Global prevalence of glaucoma and projections of glaucoma burden through 2040: a systematic review and meta-analysis. *Ophthalmology* 2014;121:2081–90.
3. Asia-Pacific Glaucoma Society. Asia Pacific Glaucoma Guidelines, 4<sup>th</sup> Edition. 2024.
4. Sakata R, Chang PY, Sung KR, et al. Prostaglandin-associated periorbitopathy syndrome (PAPS): Addressing an unmet clinical need. *Semin Ophthalmol* 2021;37:447–54.
5. Peplinski LS, Albiani Smith K. Deepening of lid sulcus from topical bimatoprost therapy. *Optom Vis Sci* 2004;81:574–7.
6. Filippopoulos T, Paula JS, Torun N, et al. Periorbital changes associated with topical bimatoprost. *Ophthalmic Plast Reconstr Surg* 2008;24:302–7.
7. Sarnoff DS, Gotkin RH. Bimatoprost-induced chemical blepharoplasty. *J Drugs Dermatol* 2015;14:472–7.
8. Kim HW, Choi YJ, Lee KW, et al. Periorbital changes associated with prostaglandin analogs in Korean patients. *BMC Ophthalmol* 2017;17:126.
9. Kim JS, Blizzard S, Woodward JA, et al. Prostaglandin-Associated Periorbitopathy in Children and Young Adults with Glaucoma. *Ophthalmol Glaucoma* 2020;3:288–94.
10. Lee YK, Lee JY, Moon JI, et al. Effectiveness of the ICare rebound tonometer in patients with overestimated intraocular pressure due to tight orbit syndrome. *Jpn J Ophthalmol* 2014;58:496–502.
11. Pasquale LR. Prostaglandin-Associated Periorbitopathy. *Glaucoma Today*. 2011. Available at: [https://glaucomatoday.com/pdfs/gt0611\\_thera\\_pasquale.pdf](https://glaucomatoday.com/pdfs/gt0611_thera_pasquale.pdf). Access date: 24/03/2022.
12. Procanoy F, M PLL, F JLB. Lower Eyelid Horizontal Tightening in Prostaglandin Associated Periorbitopathy. *Ophthalmic Plast Reconstr Surg* 2021;37:S76–9.
13. Sakata R, Shirato S, Miyata K, et al. Incidence of deepening of the upper eyelid sulcus on treatment with a tafluprost ophthalmic solution. *Jpn J Ophthalmol* 2014;58:212–7.
14. Rabinowitz MP, Katz LJ, Moster MR, et al. Unilateral Prostaglandin-Associated Periorbitopathy: A Syndrome Involving Upper Eyelid Retraction Distinguishable From the Aging Sunken Eyelid. *Ophthalmic Plast Reconstr Surg* 2015;31:373–8.
15. Tanito M, Ishida A, Ichioka S, et al. Proposal of a simple grading system integrating cosmetic and tonometric aspects of prostaglandin-associated periorbitopathy. *Medicine (Baltimore)* 2021;100:e26874.
16. PAPS Compendium Expert Advisory Meeting, 23<sup>rd</sup> July, 2022.
17. Liu C, Wong T, Leung D, et al. Clinical Staging of Prostaglandin-Associated Periorbitopathy Syndrome in Glaucoma: A Review from Asia. *Semin Ophthalmol* 2024;39:424–28.
18. Section 4.4 Side Effects of Medical Therapy, Prostaglandin-Associated Periorbitopathy. Asia-Pacific Glaucoma Society. Asia Pacific Glaucoma Guidelines, 4<sup>th</sup> Edition. 2024;133–135.
19. Davis SA, Sleath B, Carpenter DM, et al. Drop instillation and glaucoma. *Curr Opin Ophthalmol* 2018;29:171–7.
20. Inoue K. Managing adverse effects of glaucoma medications. *Clin Ophthalmol* 2014;8:903–13.
21. Inoue K, Shiokawa M, Wakakura M, et al. Deepening of the upper eyelid sulcus caused by 5 types of prostaglandin analogs. *J Glaucoma* 2013;22:626–31.
22. Kucukevcilioglu M, Bayer A, Uysal Y, et al. Prostaglandin associated periorbitopathy in patients using bimatoprost, latanoprost and travoprost. *Clin Exp Ophthalmol* 2014;42:126–31.
23. Patradul C, Tantisevi V, Manassakorn A. Factors Related to Prostaglandin-Associated Periorbitopathy in Glaucoma Patients. *Asia Pac J Ophthalmol (Phila)* 2017;6:238–42.
24. Shah M, Lee G, Lefebvre DR, et al. A cross-sectional survey of the association between bilateral topical prostaglandin analogue use and ocular adnexal features. *PLoS One* 2013;8:e61638.
25. Matsuo M, Matsuoka Y, Tanito M. Efficacy and Patient Tolerability of Omidenepag Isopropyl in the Treatment of Glaucoma and Ocular Hypertension. *Clin Ophthalmol* 2022;16:1261–79.
26. Manju M, Pauly M. Prostaglandin-associated periorbitopathy: A prospective study in Indian eyes. *Kerala Journal Ophthalmology* 2020;32:36–40.

27. Aihara M, Shirato S, Sakata R. Incidence of deepening of the upper eyelid sulcus after switching from latanoprost to bimatoprost. *Jpn J Ophthalmol* 2011;55:600–4.
28. Nouveau S, Agrawal D, Kohli M, et al. Skin Hyperpigmentation in Indian Population: Insights and Best Practice. *Indian J Dermatol* 2016;61:487–95.
29. Taketani Y, Yamagishi R, Fujishiro T, et al. Activation of the prostanoid FP receptor inhibits adipogenesis leading to deepening of the upper eyelid sulcus in prostaglandin-associated periorbitopathy. *Invest Ophthalmol Vis Sci* 2014;55:1269–76.
30. Aihara M, Aung T, Bacharach J, et al. Omidenepag isopropyl ophthalmic solution for open-angle glaucoma and ocular hypertension: an update. *Expert Rev Ophthalmol* 2021;16:243–50.
31. Zhang F, Liao S, Liu K, et al. Prostaglandin-associated periorbitopathy. *Chin J Ophthalmol* 2017;53:637–40.
32. Tan J, Berke S. Latanoprost-induced prostaglandin-associated periorbitopathy. *Optom Vis Sci* 2013;90:e245–7.
33. Lee GA, Ritch R, Liang SY, et al. Tight orbit syndrome: a previously unrecognized cause of open-angle glaucoma. *Acta Ophthalmol* 2010;88:120–4.
34. Nakakura S, Yamamoto M, Terao E, et al. Prostaglandin-associated periorbitopathy in latanoprost users. *Clin Ophthalmol* 2015;9:51–6.
35. Miki T, Naito T, Fujiwara M, et al. Effects of pre-surgical administration of prostaglandin analogs on the outcome of trabeculectomy. *PLoS One* 2017;12:e0181550.
36. Ishida A, Miki T, Naito T, et al. Surgical Results of Trabeculectomy among Groups Stratified by Prostaglandin-Associated Periorbitopathy Severity. *Ophthalmology* 2023;130:297–303.
37. Section 4.3 Novel Medications for Glaucoma Treatment, EP2 Receptor Agonist. Asia-Pacific Glaucoma Society. *Asia Pacific Glaucoma Guidelines, 4<sup>th</sup> Edition*. 2024;124–126.
38. Santen Pharmaceutical Asia Pte. Ltd. *PAPS Guidebook*. 2022.
39. Nickson D, Warhurst C, Dutton E. The importance of attitude and appearance in the service encounter in retail and hospitality. *Managing Service Quality: An International Journal* 2005;15:195–208.
40. Quittkat HL, Hartmann AS, Düsing R, et al. Body Dissatisfaction, Importance of Appearance, and Body Appreciation in Men and Women Over the Lifespan. *Front Psychiatry* 2019;10:864.
41. Adewara BA, Singh S. Ocular Adnexal Changes After Antiglaucoma Medication Use. *Int Ophthalmol Clin* 2023;63:47–58.
42. Abalo-Lojo JM, Ferreiro PV, Asorey MK, et al. Improvement of Prostaglandin-Associated Periorbitopathy after Discontinuing Treatment. *Turk J Ophthalmol* 2023;53:8–12.
43. Sakata R, Shirato S, Miyata K, et al. Recovery from deepening of the upper eyelid sulcus after switching from bimatoprost to latanoprost. *Jpn J Ophthalmol* 2013;57:179–84.
44. Yen JH, Kocieda VP, Jing H, et al. Prostaglandin E2 induces matrix metalloproteinase 9 expression in dendritic cells through two independent signaling pathways leading to activator protein 1 (AP-1) activation. *J Biol Chem* 2011;286:38913–23.
45. Oogi S, Nakakura S, Terao E, et al. One-Year Follow-Up Study of Changes in Prostaglandin-Associated Periorbital Syndrome After Switch From Conventional Prostaglandin F2alpha to Omidenepag Isopropyl. *Cureus* 2020;12:e10064.
46. Kiuchi Y, Inoue T, Shoji N, et al. The Japan Glaucoma Society guidelines for glaucoma 5th edition. *Jpn J Ophthalmol* 2023;67:189–254.
47. Sakata R, Fujishiro T, Saito H, et al. Prostaglandin-Associated Periorbitopathy Symptom Alleviation After Switching Prostaglandin F Receptor Agonist to EP2 Receptor Agonist in Patients with Glaucoma. *J Ocul Pharmacol Ther* 2023;39:63–69.
48. Beidoe G, Mousa SA. Current primary open-angle glaucoma treatments and future directions. *Clin Ophthalmol* 2012;6:1699–707.
49. Zhang N, Wang J, Li Y, et al. Prevalence of primary open angle glaucoma in the last 20 years: a meta-analysis and systematic review. *Sci Rep* 2021;11:13762.
50. Pekmezci M, Vo B, Lim AK, et al. The Characteristics of Glaucoma in Japanese Americans. *Arch Ophthalmol* 2009;127:167–71.
51. Skorin L, Jr., Dailey KH. Clicking Eyelids: A New Finding of Prostaglandin-Associated Periorbitopathy. *Optom Vis Sci* 2016;93:779–81.
52. Doucette LP, Walter MA. Prostaglandins in the eye: Function, expression, and roles in glaucoma. *Ophthalmic Genet* 2017;38:108–16.
53. Gatton DD, Sagara T, Lindsey JD, et al. Increased matrix metalloproteinases 1, 2, and 3 in the monkey uveoscleral outflow pathway after topical prostaglandin F(2 alpha)-isopropyl ester treatment. *Arch Ophthalmol* 2001;119:1165–70.
54. Oh D-J, Martin JL, Williams AJ, et al. Analysis of Expression of Matrix Metalloproteinases and Tissue Inhibitors of Metalloproteinases in Human Ciliary Body after Latanoprost. *Invest Ophthalmol Vis Sci* 2006;47:953–63.
55. Richter M, Krauss AH-P, Woodward DF, et al. Morphological Changes in the Anterior Eye Segment after Long-Term Treatment with Different Receptor Selective Prostaglandin Agonists and a Prostanoid. *Invest Ophthalmol Vis Sci* 2003;44:4419–26.
56. Karli S, Ayala-Haedo JA, Feuer WJ, et al.

Effect of prostaglandin analogs on matrix metalloproteinases and tissue inhibitor of metalloproteinases in eyelid muscle specimens. *Clin Ophthalmol* 2018;12:2039–46.

57. Choi HY, Lee JE, Lee JW, et al. In vitro study of antiadipogenic profile of latanoprost, travoprost, bimatoprost, and tafluprost in human orbital preadipocytes. *J Ocul Pharmacol Ther* 2012;28:146–52.
58. Lepak NM, Serrero G. Prostaglandin F2 alpha stimulates transforming growth factor-alpha expression in adipocyte precursors. *Endocrinology* 1995;136:3222–29.
59. Reginato MJ, Krakow SL, Bailey ST, et al. Prostaglandins promote and block adipogenesis through opposing effects on peroxisome proliferator-activated receptor gamma. *J Biol Chem* 1998;273:1855–8.
60. Serrero G, Lepak NM. Prostaglandin F2alpha receptor (FP receptor) agonists are potent adipose differentiation inhibitors for primary culture of adipocyte precursors in defined medium. *Biochem Biophys Res Commun* 1997;233:200–2.
61. Yamamoto Y, Taniguchi T, Inazumi T, et al. Effects of the Selective EP2 Receptor Agonist Omidenepag on Adipocyte Differentiation in 3T3-L1 Cells. *J Ocul Pharmacol Ther* 2020;36:162–9.
62. Esaki Y, Katsuta O, Kamio H, et al. The Antiglaucoma Agent and EP2 Receptor Agonist Omidenepag Does Not Affect Eyelash Growth in Mice. *J Ocul Pharmacol Ther* 2020;36:529–33.
63. Johnstone MA, Albert DM. Prostaglandin-induced hair growth. *Surv Ophthalmol* 2002;47 Suppl 1:S185–202.
64. Abdel-Malek ZA, Swope VB, Amornsiripanitch N, et al. In vitro modulation of proliferation and melanization of S91 melanoma cells by prostaglandins. *Cancer Res* 1987;47:3141–6.
65. Kapur R, Osmanovic S, Toyran S, et al. Bimatoprost-induced periocular skin hyperpigmentation: histopathological study. *Arch Ophthalmol* 2005;123:1541–6.
66. Stjerschantz JW, Albert DM, Hu DN, et al. Mechanism and clinical significance of prostaglandin-induced iris pigmentation. *Surv Ophthalmol* 2002;47 Suppl 1:S162–75.
67. Berke SJ. PAP: New Concerns for Prostaglandin Use. *Review of Ophthalmology*. 2012. Available at: <https://www.reviewofophthalmology.com/article/pap-new-concerns-for-prostaglandin-use>. Access date: 24/03/2022.
68. Nakazawa T, Takahashi K, Kuwayama Y, et al. Interim Results of Post-Marketing Observational Study of Omidenepag Isopropyl for Glaucoma and Ocular Hypertension in Japan. *Adv Ther* 2022;39:1359–74.
69. Aihara M, Lu F, Kawata H, et al. Twelve-month efficacy and safety of omidenepag isopropyl, a selective EP2 agonist, in open-angle glaucoma and ocular hypertension: the RENGE study. *Jpn J Ophthalmol* 2021;65:810–19.
70. Aihara M, Lu F, Kawata H, et al. Omidenepag Isopropyl Versus Latanoprost in Primary Open-Angle Glaucoma and Ocular Hypertension: The Phase 3 AYAME Study. *Am Ophthalmol* 2020;220:53–63.
71. Aihara M, Ropo A, Lu F, et al. Intraocular pressure-lowering effect of omidenepag isopropyl in latanoprost non-/low-responder patients with primary open-angle glaucoma or ocular hypertension: the FUJI study. *Jpn J Ophthalmol* 2020;64:398–406.
72. Inoue K, Shiokawa M, Kunimatsu-Sanuki S, et al. Three-year efficacy and safety of omidenepag isopropyl in patients with normal tension glaucoma. *Jpn J Ophthalmol* 2024;68:206–10.
73. Ozaki H, Kobayashi A, Uchio E, et al. Three-year outcome of omidenepag isopropyl in primary open angle glaucoma and preperimetric glaucoma. *Invest Ophthalmol Vis Sci* 2024;65:1906.



**SANTEN PHARMACEUTICAL ASIA PTE. LTD.**  
**6 Temasek Boulevard, #37-01,**  
**Suntec Tower Four, Singapore 038986**  
**[www.santen.com](http://www.santen.com)**